



Intrathecal pump implantation techniques

Julie A. Sparlin, MD, Oscar A. de Leon-Casasola, MD

From the Division of Pain Medicine, Roswell Park Cancer Institute and Department of Anesthesiology, School of Medicine, University at Buffalo, Buffalo, New York.

KEYWORDS:

Intrathecal pump;
 Implantation technique

Perioperative complications associated with the implantation of intrathecal pumps can be significantly decreased through the use of a preoperative, intraoperative and postoperative protocols. This article describes the steps to be followed to limit the side effects and complications that may be associated with this procedure.

© 2011 Elsevier Inc. All rights reserved.

The possibility of implanting devices for continuous, long-term infusion was first suggested by Harbaugh et al in 1982.¹ Since then, the procedure is performed for a variety of chronic pain syndromes, and this article describes the surgical approach to performing the permanent implant of the pump and the intrathecal catheter.

Pump implantation

Preoperative care

As with the epidural trial, pump implantation begins with the administration of prophylactic antibiotics 1-2 hours before starting the procedure. For this purpose, 1 g of intravenous (IV) cefazolin is given. In patients who are allergic to penicillin, 600 mg of IV clindamycin may be used. Moreover, if a patient is known to be a carrier of methicillin-resistant *Staphylococcus aureus*, mupirocin 2% nasal ointment should be used. These patients should apply half of the ointment from a single-use tube of nasal ointment into one nostril and the other half into the other

nostril. This treatment is repeated twice daily for 5 days. Preemptive analgesia is also implemented in these patients with 400 mg of oral (PO) celecoxib² and 600 mg of PO gabapentin or 150 mg of PO pregabalin.^{3,4}

Intraoperative care

The patient may receive general anesthesia, or the procedure may be performed under local anesthesia with sedation. Patients with severe long-term pain may develop central sensitization and tend to have a lower threshold for pain; thus, performing this procedure under local anesthesia and sedation may be difficult. Consequently, we perform this procedure under general anesthesia in these patients. The patient is placed in the prone position with a pillow under the abdomen to straighten out the lordotic curvature of the lumbar spine. Fluoroscopy evaluation of the spine is then performed, and a site for needle insertion is chosen. Likewise, the vertebral body at which the tip of the catheter will end is marked with an electrocardiogram pad to facilitate the final placement position (Figure 1). Sterile preparation of the skin and drape placement are then performed. If general anesthesia is used, an IV ketamine infusion is also used, with a dosage of 10 µg/kg/min. The infusion is stopped 30 minutes before the completion of the surgical procedure.

Address reprint requests and correspondence: Julie A. Sparlin, MD, Roswell Park Cancer Institute, Elm and Carlton Streets, Buffalo, NY 14263.

E-mail address: jsparlinmd@yahoo.com.

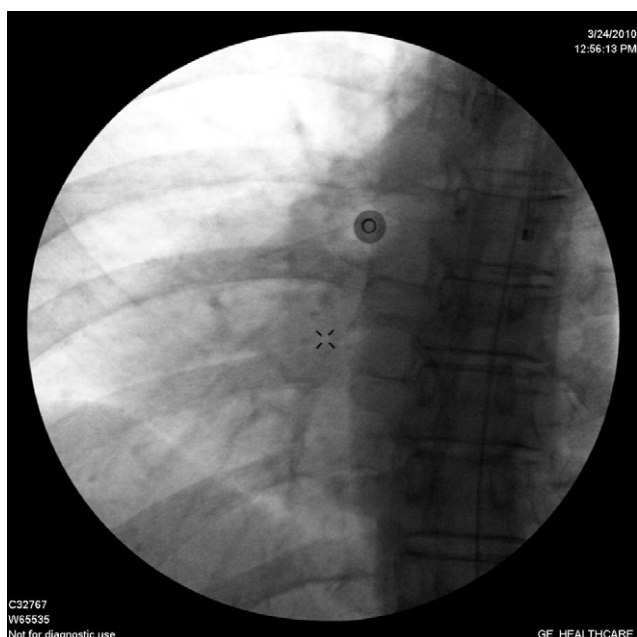


Figure 1 An electrocardiogram pad is placed lateral to the spine corresponding to the vertebral body at which level the tip of the intrathecal catheter will be advanced.

Catheter placement

The incision site is infiltrated with 0.25% bupivacaine, and a 2-4-cm paramedian incision is performed with a 15 blade on a scalpel at the site that had previously been selected. The skin incision is deepened into the subcutaneous tissue with the use of electrocautery, and Senn retractors are used to expose deeper tissues. Dissection is carried out with the use of electrocautery set at no more than 25 W to

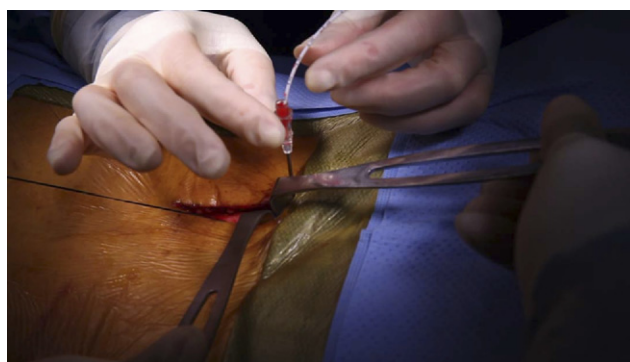


Figure 3 The dedicated intrathecal catheter is inserted once free-flowing cerebrospinal fluid is obtained. Tip advancement is always done under direct fluoroscopy guidance, and any resistance demands evaluation of the tip of the catheter by obtaining a lateral view of the spine, as this may be a sign of anterior migration.

dissect down to the fascia of the paraspinal muscle. A small pocket on one side to accommodate the curvature of the catheter is performed. The anatomy of the site is reassessed with fluoroscopy, and a dedicated 15-gauge intraspinal needle is inserted via a paramedian approach (Figure 2). The needle is advanced until the intrathecal space is reached; cerebrospinal fluid (CSF) in the hub of the needle confirms intrathecal needle tip placement (Figure 3). The dedicated intrathecal catheter is introduced through the needle using fluoroscopy to guide placement of the catheter tip at the appropriate level, which had been previously marked with the electrocardiogram electrode (Figure 4). Alternatively, if the infusion is targeting the lower lumbar or the sacral area, a retrograde approach is used (Figure 5). A Weitlaner retractor is placed in the wound to expose the area around the needle, and a purse-string suture with 2-0 silk is placed

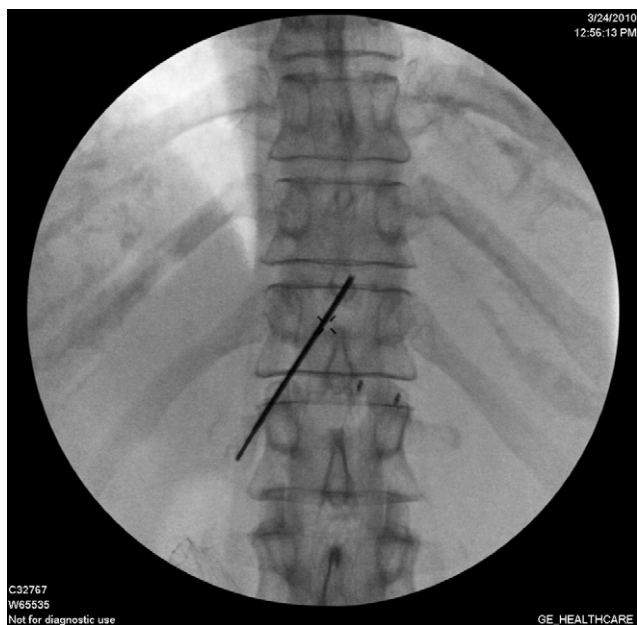

Figure 2 A paramedian approach is always used to access the intrathecal space. Note the position of the tip of the Tuohy needle in relation to the base of the spinous process.

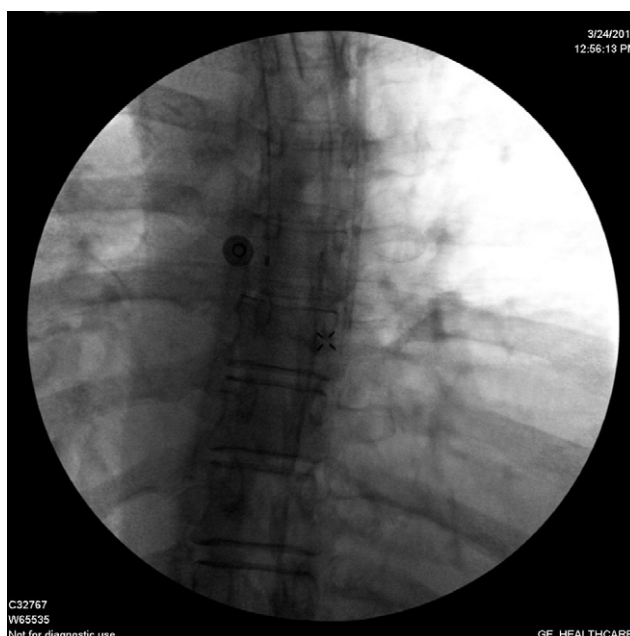

Figure 4 Tip of the catheter in the final desired position.

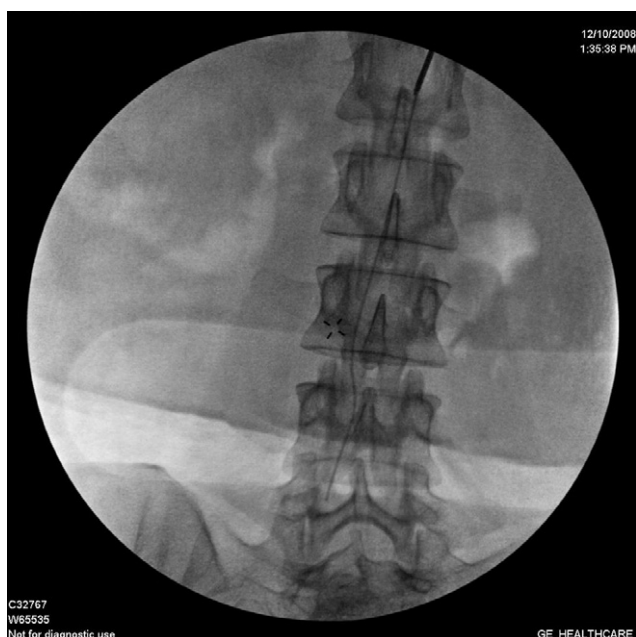

Figure 5 Insertion of the intrathecal catheter with a retrograde approach. Again, note the position of the tip of the Tuohy needle in relation to the upper portion of the spinous process.

around the needle. The needle is removed with care so that the catheter is not withdrawn during the process; catheter tip location is again evaluated with the use of fluoroscopy.

Once the needle is out, close the purse-string suture and tie it off. The purpose of the purse-string suture is 2-fold; it helps to prevent dislodgment and minimizes seroma formation secondary to CSF backtracking along the path of the catheter. CSF return from the distal end of the catheter is evaluated; if there is no backflow, a 25-gauge needle may be inserted into the distal end of the catheter, and gentle aspiration with a 3-mL syringe is done until CSF is obtained; this confirms both intrathecal placement and the absence of kinks in the catheter.

The end of the catheter is clamped with a Halsted mosquito clamp, and the catheter is secured via a dedicated butterfly anchor to fascia with 2-0 silk. The kit comes with 2 anchors; both of them may be used if there are any

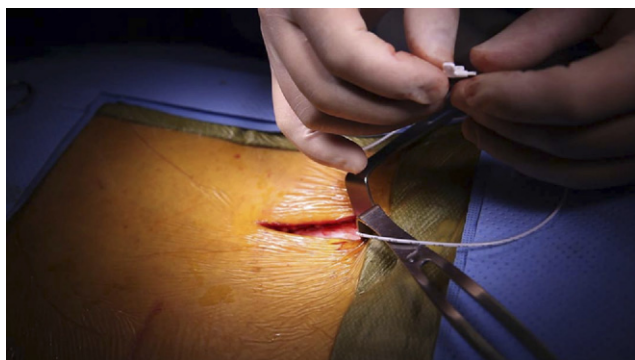


Figure 6 Insertion of the fixation device through the intrathecal catheter.

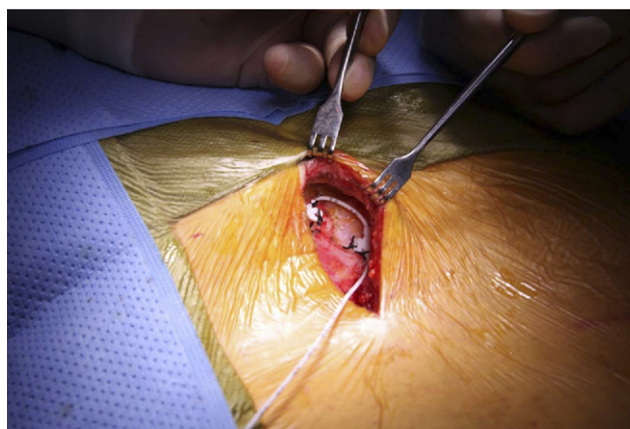


Figure 7 Fixation devices in place sutured to the muscular fascia.

concerns that the catheter might kink, or if the patient has very little subcutaneous tissue so as to avoid catheter impingement on the skin (Figures 6 and 7).

Pump implantation

Once the catheter is secured in place, the pump is implanted. We prefer to implant the pump in the supragluteal region because it allows the patient to remain in the prone position throughout the procedure, pump refills are easy, and there is a lack of migration and tendency to flip over that is more likely when placed in the abdomen. The incision is performed at the level of the superior aspect of the iliac bone. The medial boundary is 2 cm from the posterior superior iliac spine. Infiltration of the incision site with 10-12 mL of 0.25% bupivacaine is followed by an incision just long enough to accommodate the widest aspect of the pump. Dissection down to fascia is not necessary in this area, and it is carried down 2 cm below the skin with the use of electrocautery (Figure 8). The pocket is created with the use of electrocautery at all times, with periods of rest to avoid a significant increase in the temperature of the tissues while the dissection is performed. Hemostasis is maintained at all times, and a Richardson retractor is used in the final

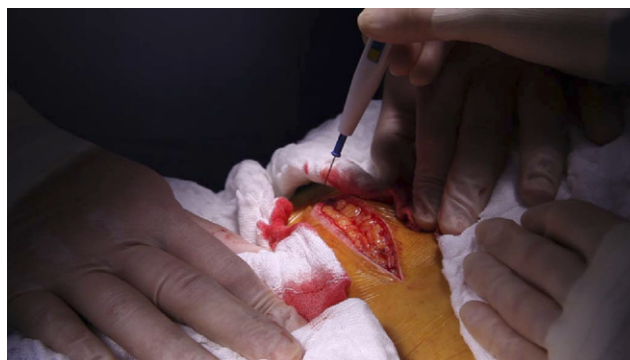


Figure 8 Dissection for the creation of a pocket for the pump. Note the use of electrocautery in the coagulation mode at all times to avoid the formation of seromas.

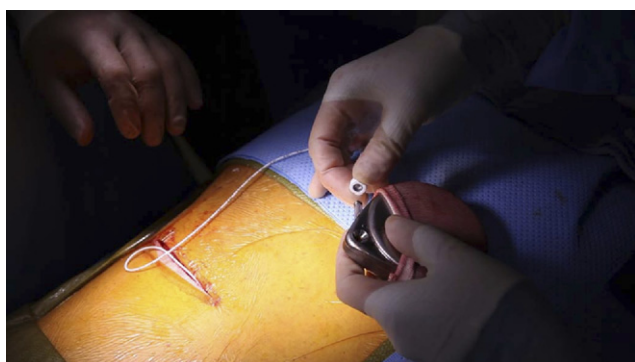


Figure 9 Connection of the intrathecal catheter with a dedicated device to the intrathecal pump.

stages of the dissection to have full visualization of the area to avoid injury to the superficial gluteal artery. Once the pocket is finished, dissection is also carried out at the upper portion of the incision to facilitate closure. The spinal needle, initially used to place the catheter, is then inserted at the pocket site, and it is directed toward the paramedian incision until it exits at a point at which it will not produce kinking of the catheter loop. The intrathecal catheter is then inserted into the needle and brought back to the pocket site, and then the needle is removed. A dedicated boot is inserted on the catheter, and the tip is then inserted into the connecting device. A 3-mL syringe is used to withdraw CSF from the connecting device as further confirmation of intrathecal catheter tip placement. The connecting device is attached to the pump (Figure 9), which should have been by now filled with the appropriate drug(s) on the back table.

Both wounds are irrigated with 50,000 U of bacitracin in 1 L of normal saline. The pump is placed within its mesh casing and then into the wound.

When using the supragluteal placement, there is no need to affix the pump to the adjacent tissues. When using the abdominal site, however, fixation to the fascia is a must to avoid migration and/or flipping. The wounds are closed in two layers: 3-0 vicryl for the subcutaneous tissue, and either staples or a running subcuticular suture with 5-0 monocryl for the skin. Once the wounds are dressed but before waking up the patient, the pump is programmed to deliver a bolus dose and the appropriate amount of medication. The bolus dose is critical to clear the dead space of both the intrathecal catheter and the pump.

Barring any intraoperative complications or exacerbation of comorbidities, patients may be discharged home on the same day of the surgery after meeting postoperative discharge criteria. Prescriptions for an antibiotic and PO pain medications for surgical pain are appropriate. The patient is instructed to keep the dressings clean and dry (ie, sponge baths and to return to clinic in 7-10 days for a postoperative visit and to remove staples if used. Patients then only need to return for pump refills as frequently as determined by the rate of infusion that has been programmed into the pump.

References

1. Harbaugh RE, Coombs DW, Saunders RL, et al: Implanted continuous epidural morphine infusion system: Preliminary report. *J Neurosurg* 56:803-806, 1982
2. Shen B, Tang X, Yang J, et al: Effects of perioperative administration of celecoxib on pain management and recovery of function after total knee replacement. *Chin J Surg* 47:116-119, 2009
3. Kohli M, Murali T, Gupta R, et al: Optimization of subarachnoid block by oral pregabalin for hysterectomy. *J Anaesthesiol Clin Pharmacol* 27:101-105, 2011
4. Buvanendran A, Kroin JS: Multimodal analgesia for controlling acute postoperative pain. *Curr Opin Anaesthesiol* 22:588-593, 2009